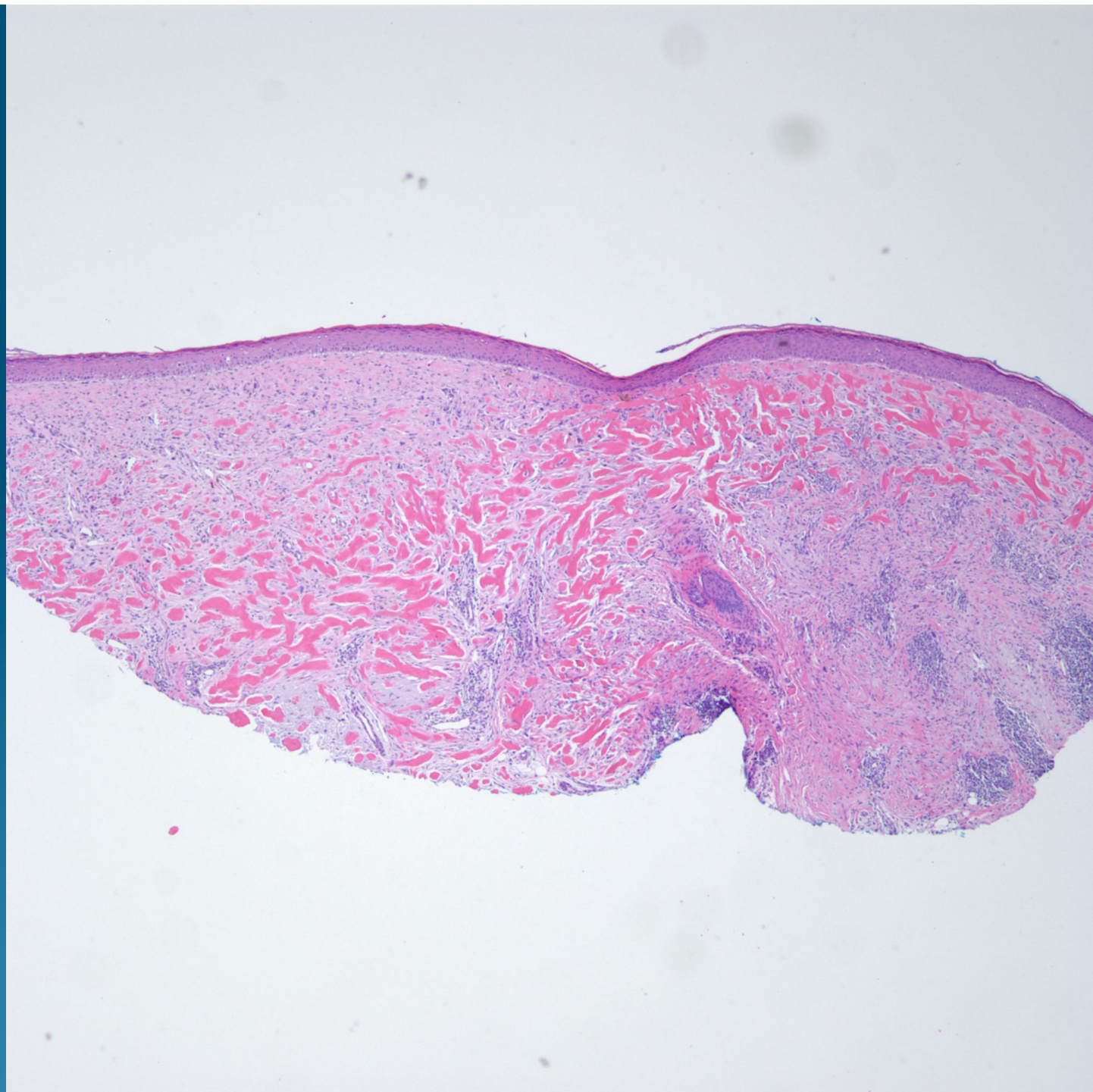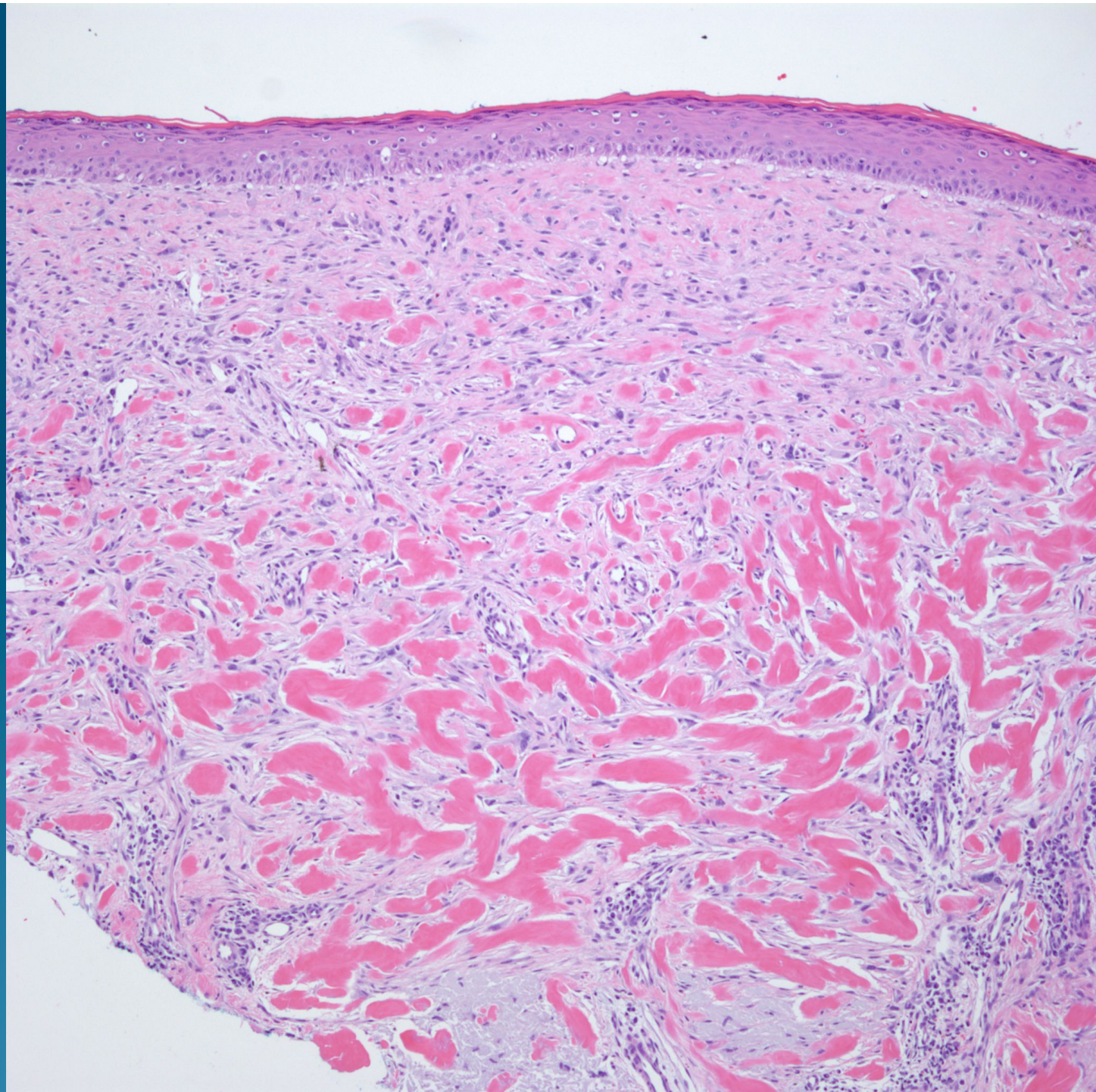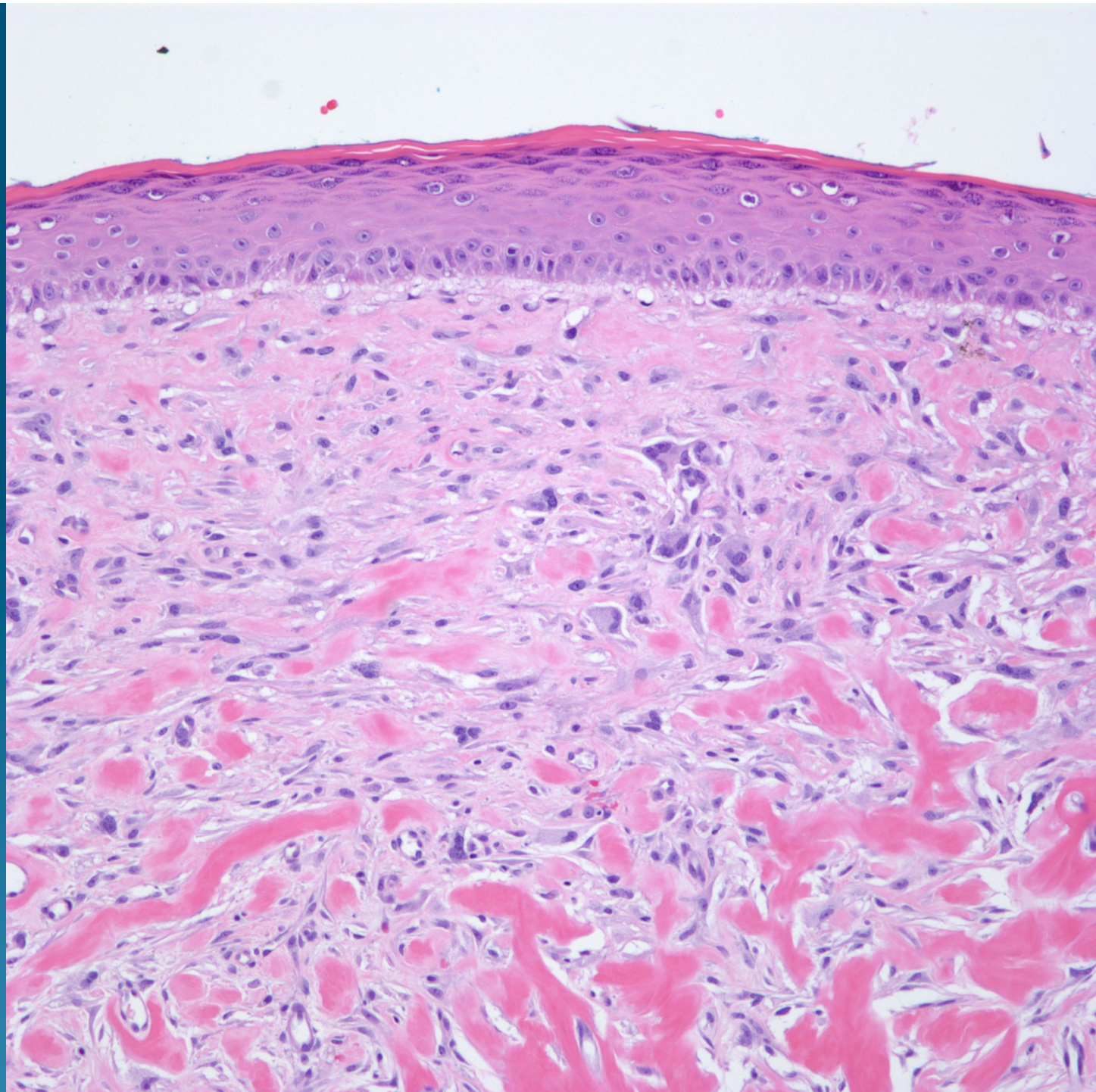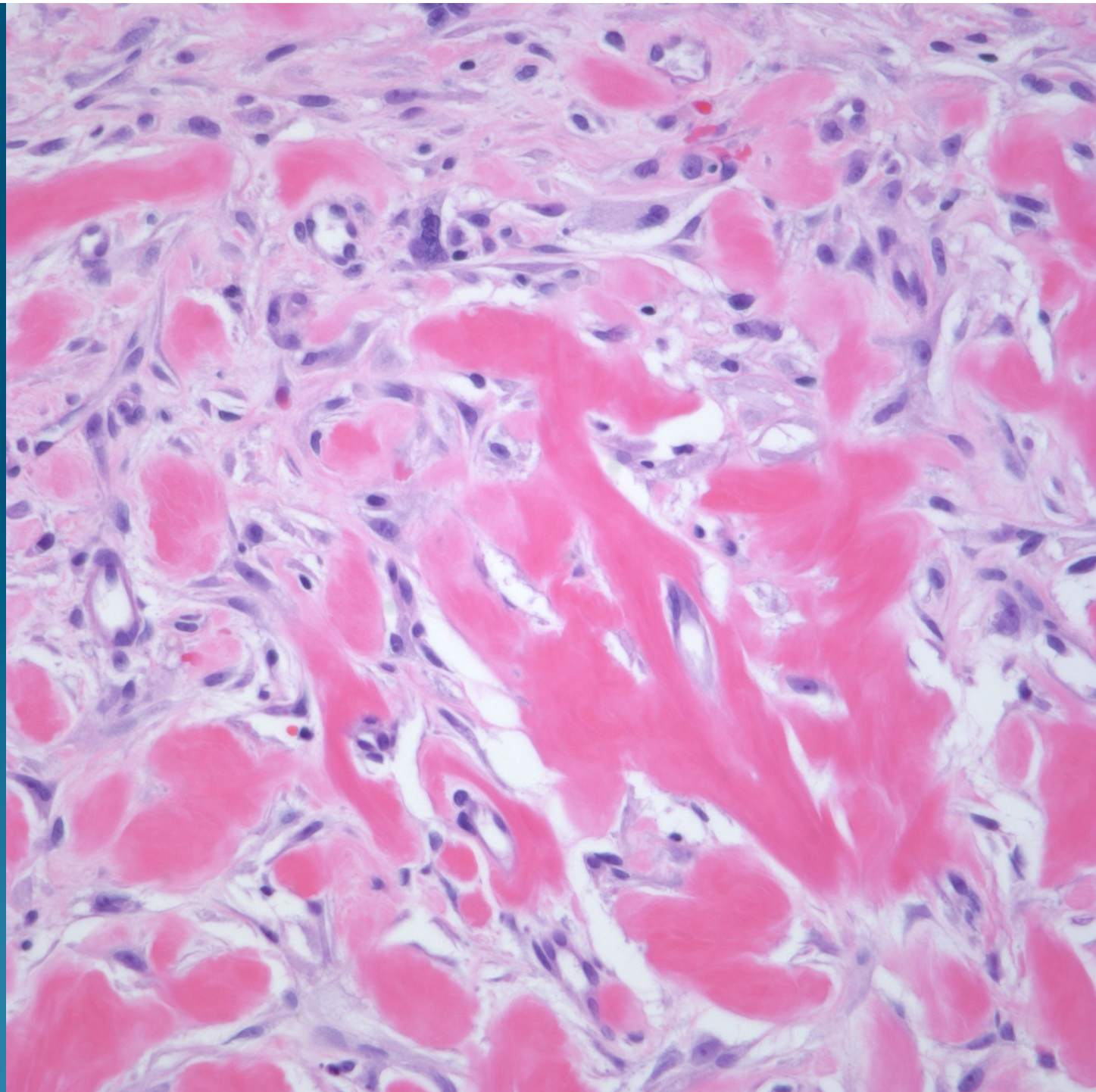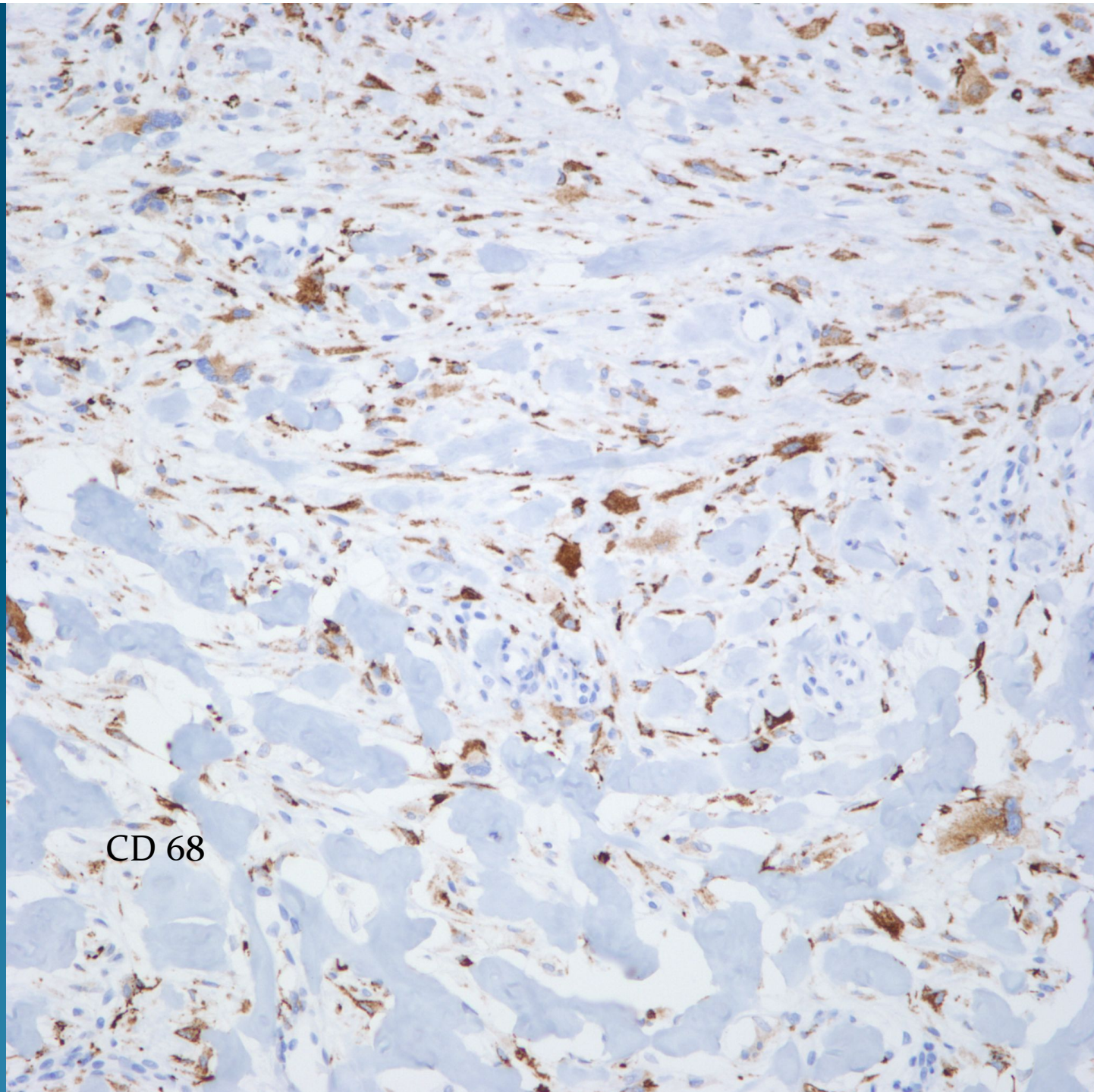


CD 68



Atypical Fibroxanthoma with Keloidal Collagen Changes

Notes

- This is a recently described variant of an atypical fibroxanthoma, which, in the absence of prior trauma or biopsy, shows this peculiar keloidal collagen bundles.
- Similar changes have been described in desmoplastic melanomas, basal cell carcinomas, and squamous cell carcinomas necessitating additional immunohistochemical stains to confirm the diagnosis
- There does not appear to be a difference in prognosis or behavior of this rare variant.
- J Cutan Pathol. 2009 May;36(5):535-9. Epub 2009 Mar 30.